79 Human Papillomaviruses

Reinhard Kirnbauer and Petra Lenz

Synonyms: ■ Verrucae vulgares (singular: verruca vulgaris) – common warts ■ Verrucae palmares et plantares – hand and foot warts ■ Verrucae planae – flat warts, plane warts ■ Condylomata acuminata (singular: condyloma acuminatum) – genital warts ■ Condylomata plana – flat cervical condylomas, plane condylomas ■ Squamous intraepithelial lesion (SIL) – cervical intraepithelial neoplasia (CIN); vulvar (VIN); vaginal (VaIN); penile (PIN or PeIN); anal (AIN) ■ Buschke–Löwenstein tumor – giant condylomata acuminata, condylomata acuminata gigantea ■ Florid oral papillomatosis – Ackerman tumor ■ Papillomatosis cutis carcinoides – Gottron tumor ■ Focal epithelial hyperplasia – Heck disease

Key features

- Human papillomaviruses (HPVs) comprise a large group of more than 200 genotypes that infect the epithelia of skin or mucosa and most commonly cause benign papillomas or warts
- Epidermodysplasia verruciformis (EV) is an inherited disease characterized by generalized flat warts or pityriasis versicolor-like macules, caused by chronic infection with HPV types in the genus β; patients often develop squamous cell carcinomas (SCCs) in sun-exposed areas
- EV-associated HPV types are also detected in skin cancers and normal skin. These viruses are activated by UV exposure, immunosuppression, and specific host genetic background (EV)
- Anogenital HPV is a highly prevalent, sexually transmitted infection (STI) seen predominantly in young adults. Condylomata acuminata or benign anogenital warts are typically caused by HPV-6 or -11, which are considered to be low-risk types
- Persistent infection with high-risk HPV types, predominantly HPV-16 and -18, is the major cause of cervical and anal cancers, a subset of vaginal, vulvar, penile, and oropharyngeal cancers, and rarely digital SCCs
- Patients with cellular immunodeficiencies are at higher risk for persistent HPV infection and progressive disease
- No effective specific antiviral treatment for warts exists, and most therapies focus on destruction of visible lesions or induction of a cellular immune response
- Highly effective prophylactic HPV vaccines based on virus-like particles (VLPs) have been licensed for the prevention of genital warts and/or HPV-associated anogenital cancers

INTRODUCTION

Papillomaviruses are a large group of DNA viruses that are widely distributed in animals and humans, most commonly inducing benign papillomas or warts[1]. Recurrent skin and anogenital warts may be disfiguring, impose a considerable psychological burden, and are a frequent cause of medical office visits. A subset of human papillomaviruses (HPVs) designated as high-risk types, most often HPV-16 and -18, is now recognized as the primary etiologic agent for: cervical cancer and its precursor lesions; a subset of malignancies at other anogenital sites and in the upper aerodigestive tract; and, rarely, squamous cell cancer (SCC) of the digits. In contrast, infection with the common cutaneous HPV types 1, 2, 4, 27, 57, etc. is not thought to have any oncogenic potential[1]. In immunocompromised patients, HPV infections tend to persist and result in an increased risk of anogenital neoplasias. The high prevalence of genital HPV infection in sexually active young adults is a major concern, as effective antiviral treatments do not exist. More than two decades ago, prophylactic vaccines based on virus-like particles (VLPs) that prevent transmission in animal models of papillomavirus infection were developed[2–4]. Human vaccine studies subsequently demonstrated safety and nearly complete (>90%) efficacy in preventing vaccine type-restricted genital HPV infection and the development of associated neoplasias[5–7].

History

An infectious etiology for human warts had long been suspected[1], and experimental transmission of common warts with a cell-free extract was demonstrated over 100 years ago[8]. The descriptions of cottontail rabbit papillomavirus (CRPV) in 1933 and the rare genodermatosis *epidermodysplasia verruciformis* (EV) demonstrated the oncogenic potential of papillomaviruses. Following the cloning of the first papillomavirus genome in the late 1970s, the plurality of human and animal papillomaviruses became evident[9]. Based on genome sequencing, HPV types can be grouped into phylogenetic trees with a remarkable relationship to biologic behavior, e.g. mucosal and cutaneous types, high-risk and low-risk genital HPV, and EV-associated HPV[9]. Today, the genomes of more than 200 HPV types have been fully characterized and additional partial DNA sequences have been obtained, indicating the existence of at least 200 HPV genotypes[10]. In 1976, zur Hausen proposed an association between papillomaviruses and cervical cancer[11], and subsequent molecular studies led to the recognition of a subset of HPV types in a high proportion of cervical carcinomas. The identification of biologic differences between "high-risk" and "low-risk" mucosal HPV confirmed that infection with oncogenic HPV was the main cause of cervical cancer and its precursor lesions[12].

EPIDEMIOLOGY

Cutaneous warts are caused by a small group of specific HPV types, with a prevalence of up to 30% in primary schoolchildren and a decline thereafter with increasing age[13–15]. Patients living in larger households often report an infected cohabitant, supporting the concept of person-to-person transmission. The majority of warts will regress spontaneously within 1–2 years. After clearance occurs, reinfection with the same HPV type appears to be uncommon, suggesting that protective type-restricted immunity may develop.

Genital infection with HPV occurs most commonly by intimate contact, while infection of non-genital skin may occur via direct skin-to-skin contact or indirectly through contaminated surfaces and objects (e.g. swimming pool, gymnasium). Basal keratinocytes, which serve as the primary targets for HPV infection, are exposed to the virus through minor abrasions, and infection is promoted by maceration. Autoinoculation of virus from the lesion to adjacent skin is observed frequently, especially for digital or flat warts. Using sensitive polymerase chain reaction (PCR)-based detection, normal-appearing skin surrounding HPV-associated lesions and even skin of healthy volunteers may contain HPV DNA. These observations help to explain the high recurrence rate of warts (e.g. 20%–50% for genital condylomata) and the observation that treatment may not prevent further transmission of the virus. Papillomaviruses are resistant to heat and desiccation due to the absence of a viral envelope, and even laser fumes may contain infectious virions[16].

Genital warts in prepubertal children are uncommon and their diagnosis raises special concerns. Although viral transmission may occur during delivery, from close family contacts, or by autoinoculation

Downloaded for Anonymous User (n/a) at Egyptian Knowledge Bank from ClinicalKey.com by Elsevier on March 10, 2024. For personal use only. No other uses without permission. Copyright ©2024. Elsevier Inc. All rights reserved.

from skin warts, the possibility that these lesions may have been caused by sexual abuse should always be carefully considered (see below)[17].

In the US, HPV infection of the lower anogenital tract was the most common sexually transmitted infection (STI)[18–21], with a historical overall prevalence of ~40% in those ages 19–59 years[18]. However, following the introduction of the quadrivalent HPV vaccine, the prevalence of HPV types 6, 11, 16, and 18 in cervicovaginal specimens decreased in women ages 14–19 years, declining from 11.5% in the prevaccine era (2003–2006) to 5% in the years 2007–2010[19]. Behavioral risk factors include sexual intercourse at an early age and the number of lifetime sexual partners[9]. Circumcised men are less likely to carry and transmit HPV infection. In men who have sex with men (MSM), anal HPV infection is very prevalent (up to 75%). The public health impact of genital HPV infection is evidenced by the high number of initial visits to physicians' offices for treatment of genital warts and the frequency of consequences such as abnormal Pap smears and cervical neoplasia. In the US, the estimated prevalence of sexually acquired HPV infection is 42 million people and the estimated annual cost burden of genital HPV infection is $6 billion, making it the second most costly STI after HIV infection[20].

Most genital papillomavirus infections resolve spontaneously, whereupon HPV DNA becomes undetectable by PCR. The median duration of high-risk HPV infections in women is 8 months and persistence is found in 30% after 1 year and in 9% after 2 years[9]. Persistent cervical infection with a high-risk HPV type is required for the development of cervical intraepithelial neoplasia (CIN) and carcinoma. HPV-16 is detected in ~50% of cervical cancers and high-grade CIN. Together, HPV-16, -18, -31, -33, -45, -52, and -58 have been identified in ~90% of cervical cancers[9], and all are targeted in the nine-valent HPV vaccine.

Worldwide, an estimated 570 000 cases of cervical cancer were diagnosed in 2018, resulting in about 310 000 deaths[22]. The disease occurs predominantly in low-income countries that lack effective cervical screening programs. In the US, prevention and early detection programs have reduced the incidence rate of cervical cancer by ~75%, to 8 per 100 000 women per year. According to the American Cancer Society, an estimated 14 500 new cases of cervical cancer occurred in 2021, resulting in ~4300 deaths. Although high-risk oncogenic HPV types account for most of the observed risk for developing cervical cancer, smoking, cervical inflammation, parity, and oral contraceptive use have been proposed as cofactors[9]. While there is little evidence for hematogenous spread of HPV, ~60% of patients with anogenital infections develop low-titer, type-restricted antibodies during the course of infection[23]. Titers tend to decrease slowly and may persist for years after viral clearance.

Immune suppression in HIV-infected patients and organ transplant recipients results in HPV infections that are more frequent, persistent, and likely to progress to intraepithelial neoplasia, with $CD4^+$ T cell depletion and HIV viral load being important risk factors. In studies analyzing anal swabs, up to 93% of HIV-seropositive MSM were positive for HPV DNA, compared to 60% of HIV-negative MSM[24]. HPV-associated anal intraepithelial neoplasia (AIN), a likely anal cancer precursor, is found in up to a third of HIV-infected MSM, compared to 20% of HIV-negative MSM. Antiretroviral therapy has shown no or only a modest beneficial effect on the incidence and progression of AIN or CIN. Similarly, organ transplant recipients are at an increased risk for developing warts and genital neoplasias[25]. They also have a higher incidence of premalignant and malignant skin neoplasias, e.g. actinic keratoses, Bowen disease, and SCCs, especially in sun-exposed areas.

Cutaneous tumors from organ transplant recipients as well as "healthy skin" and plucked hairs from immunocompetent patients often contain DNA from β HPV types (see below)[9,25]. Only in patients with EV and immunocompromised hosts do β HPV infections result in highly active viral replication with cytopathic effects and clinical lesions[25]. In skin swab samples, children from 1 month to 4 years of age have a high prevalence (from 50% to 70%) of HPV DNA[26], indicating that normal-appearing human skin is colonized with a multiplicity of β HPV types very early in life, most likely through close skin-to-skin contact. Beta HPV DNA has also been detected in psoriatic lesions[27] and skin cancers from PUVA-treated patients; however, highly sensitive PCR-based methods were required for detection and viral gene transcription has not been reported.

Recurrent respiratory papillomatosis (RRP) is characterized by exophytic lesions of the airways. It occurs in juvenile- and adult-onset forms and is usually caused by HPV-6 and -11. Despite its low incidence of 0.4–1.2 per 100 000[18], RRP is the most common benign tumor of the larynx. It is believed that in childhood-onset RRP, vertical HPV transmission from mother to child occurs by aspiration during delivery through an infected birth canal[28]. Although treatment should be considered in pregnant women with condylomata in order to reduce viral load, there is insufficient evidence to support cesarean section to prevent development of RRP in the offspring. Adult-onset RRP more likely results from genital-to-oral transmission.

PATHOGENESIS

Papillomavirus Evolution

Historically, papillomaviruses were grouped together with polyomaviruses, but their fundamentally different biology and genetic organization resulted in their reclassification as a separate family in 2000[10]. The National Center for Biotechnology Information (NCBI) nucleotide sequence database (www.ncbi.nlm.nih.gov) and the Karolinska Institutet International HPV Reference Center (www.hpvcenter.se) currently list more than 200 different HPV types as well as numerous incompletely characterized putative newer HPV types. By definition, a novel type has more than 10% dissimilarity from any previously characterized type in the DNA sequences of three HPV genes (E6, E7, and L1). Dissimilarity of 2%–10% is defined as a subtype, and <2% as a variant[10].

By comparing DNA sequences in conserved portions of the papillomavirus genomes across different types, a phylogenetic tree establishing the degree of relatedness among these types has been generated[10]. Two general, the α- and β-papillomaviruses, encompass almost all known HPV types, with the genus α containing mucosal and cutaneous HPV types that are pathogenic in normal hosts and the genus β containing the types associated with EV; γ, μ, and ν genera contain additional cutaneous types. Within each genus, HPV types are grouped according to sequence homology into species, which often share similar biologic and pathologic properties (e.g. HPV-16 and -31). Present models postulate that HPVs co-evolved with our human ancestors and novel HPV types or variants were generated through either genetic drift or natural selection via adoption of specialized ecologic niches. Genetic recombination between HPV types does not occur.

Virology

Papillomaviruses are non-enveloped, double-stranded DNA viruses ~55–60 nm in diameter[9]. The spherical capsid is composed of two virally encoded proteins: the major structural protein L1 and the minor structural protein L2. During virion assembly within cells, L1 proteins form pentamers called capsomeres, and 72 capsomeres multimerize to form the viral capsid with an icosahedral symmetry arranged on a $T = 7$ surface lattice. The capsid surrounds the viral DNA, thereby protecting it from degradation, and it also enables the virus to bind efficiently to target cells. Packaged viral DNA is associated with L2 and cellular histones, forming a mini chromosome. In contrast, the early (E) viral proteins are not incorporated into infectious virions.

When expressed in cell culture, the L1 major capsid proteins of papillomaviruses self-assemble into VLPs that are morphologically similar to native virions (Fig. 79.1)[3]. Papillomavirus VLPs display type-restricted and neutralization epitopes that are used to detect serum antibodies and as the basis for prophylactic vaccines (see below)[4,29].

The HPV genome, ~8 kilobases (kb) in length, is composed of three domains: the upstream regulatory region (URR), the early region, and the late region (Fig. 79.2). The URR, ~1 kb in length, lacks open reading frames (ORFs) and contains the origin of replication and many of the control elements for transcription and replication. The early region, ~4 kb in length, contains the ORFs for genes expressed early in the papillomavirus life cycle. The late region, ~3 kb in length, encodes the capsid proteins (see above)[9].

Papillomavirus Life Cycle

The papillomaviruses are highly species-specific, and productive infection has not been observed outside natural host tissue. The papillomavirus life cycle is completed only in fully differentiated squamous epithelia. This has impeded its study in monolayer tissue culture cells, where late gene expression and virion production do not occur. Only

Downloaded for Anonymous User (n/a) at Egyptian Knowledge Bank from ClinicalKey.com by Elsevier on March 10, 2024. For personal use only. No other uses without permission. Copyright ©2024. Elsevier Inc. All rights reserved.

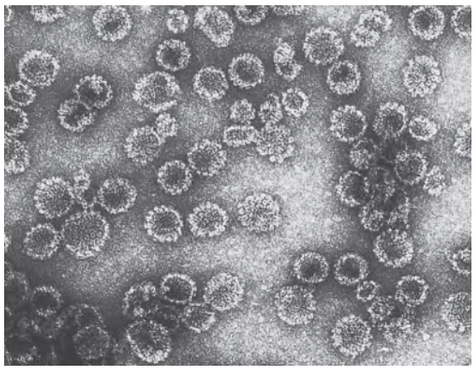

Fig. 79.1 Transmission electron photomicrograph of purified HPV-16 virus-like particles (VLPs). A prophylactic vaccine that contains HPV-6, -11, -16, -18, -31, -33, -45, -52, and -58 VLPs has been approved for the prevention of anogenital warts and cancers. Following expression in cell culture, the L1 capsid protein self-assembles into VLPs (empty capsids ~50 nm in diameter devoid of HPV DNA) that display type-restricted and neutralization surface epitopes similar to native virions. *Courtesy Saeed Shafti-Keramat.*

a small number of HPV types have been successfully propagated in mouse xenograft or raft culture systems, and limited amounts of infectious virions have been generated[9].

Productive infection and induction of hyperproliferation are initiated when the virus enters proliferating basal epithelial cells (Fig. 79.3). This layer of cells is not normally accessible to the virus because of the mechanical barrier provided by the overlying differentiated cell layers. Therefore, it is likely that infection requires an abrasion or other trauma to the epithelium to expose the basal cells to the virus. Our knowledge about early steps of infection such as viral entry and uncoating is limited. The receptor(s) that mediate virus binding to epithelial cells have not been definitively identified, but binding appears to depend on the L1 major capsid protein, and cell surface and/or basement membrane heparan sulfate is necessary for efficient infection *in vitro*[30,31]. The amino terminus of the L2 minor capsid protein is then cleaved by furin (a proprotein convertase), which exposes both a cross-neutralization epitope on L2 and a binding site (thought to be on L1) that facilitates viral entry via a putative secondary receptor on keratinocytes[31,32]. Upon infection, the covalently closed circular DNA genome becomes established as a low-copy autonomous replicon in the nuclei of basal cells, thereby creating a long-term reservoir of viral DNA.

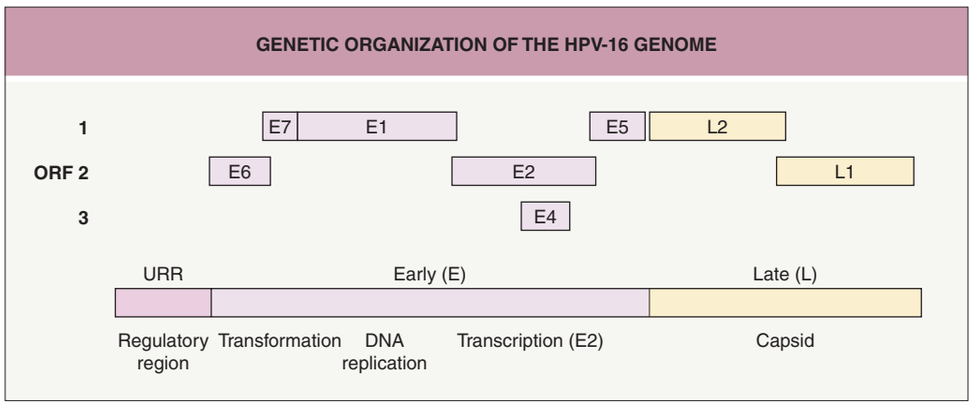

Fig. 79.2 Genetic organization of the HPV-16 genome. This is a linearized map of the 7.9 kb circular double-stranded genome. All open reading frames (ORFs) reside on one strand. Early (E) and late (L) regions are indicated. The upstream regulatory region (URR) contains the origin of replication and control elements for transcription and replication.

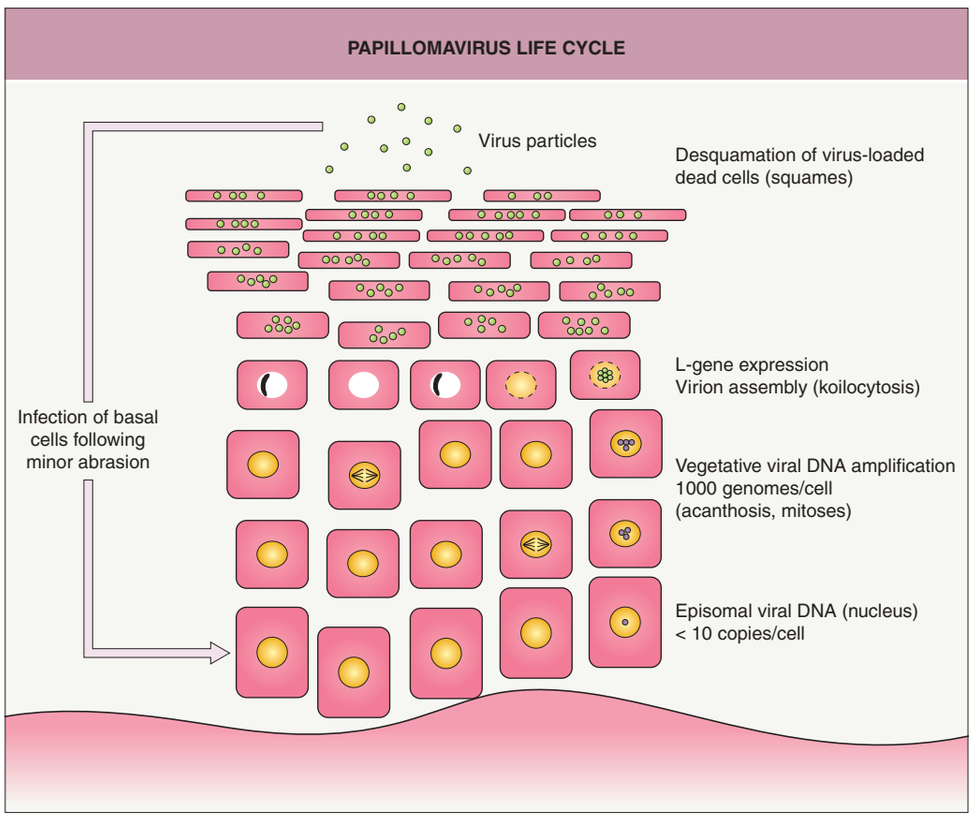

Fig. 79.3 The papillomavirus life cycle. The figure depicts a productive (virion-producing) benign wart. *Adapted from Orth G. Epidermodysplasia verruciformis. In: Salzman NP, Howley PM (eds). The Papovaviridae: Volume 2 The Papillomaviruses. New York: Plenum Press; 1987:199–243.*

Downloaded for Anonymous User (n/a) at Egyptian Knowledge Bank from ClinicalKey.com by Elsevier on March 10, 2024. For personal use only. No other uses without permission. Copyright ©2024. Elsevier Inc. All rights reserved.

The program of viral gene expression is intimately linked to the differentiation state of the infected cells. The E genes are transcribed at low levels in the basal cell layer and spinous layer. The first genes to be expressed following infection are the E1 and E2 genes, which are responsible for controlling the transcription of other viral genes and replication of the viral genome. HPVs do not encode the enzymes required for transcription or replication of viral DNA. Consequently, HPV is entirely dependent on the co-opting of cellular machinery for these functions. One major effect of HPV proteins E5, E6, and E7 is that the epidermal cell cycle, which is normally blocked for cells that are suprabasal, continues so that HPV genome copy number can be amplified to high levels during vegetative viral replication for assembly into virions (see Fig. 79.3). The E6 and E7 proteins of the high-risk mucosal HPV types act as viral oncoproteins, but no such functions are associated with the corresponding proteins of the low-risk mucosal and EV types[9]. There is limited understanding of possible differences between oncogenic (e.g. HPV-5, -8) and the non-oncogenic β HPV types.

In combination with other cellular proteins, E6 from high-risk mucosal HPV causes the ubiquitin-mediated degradation of the cellular protein p53. Elevated levels of p53 arrest cells in the G1 phase of the cell cycle or induce apoptotic cell death, so that E6-facilitated destruction of p53 removes a brake on suprabasal cell cycling. One of the principal effects of high-risk mucosal HPV E7 is to bind to the underphosphorylated form of RB (the retinoblastoma tumor suppressor protein). A physiologic role of underphosphorylated RB is to bind to and inhibit the function of the E2F transcription factor (see Fig. 107.4). When HPV E7 binds RB, E2F is liberated from this inhibition and is thereby able to induce the expression of genes required for DNA replication. Both E6 and E7 are multifunctional proteins, and while their effects on p53 and RB are critical ones, additional targets are also important to the oncogenic potential of the virus. These include activation of telomerase by E6, binding of histone deacetylases by E7, and synergistic effects of both proteins that lead to centrosome abnormalities and chromosomal instability[9].

The genes for the virion structural proteins, i.e. the late (or L) genes, are expressed in the terminally differentiated superficial layers of the epithelium. The more superficial epithelial layers also have higher levels of expression of E1 and E2 and amplification of viral DNA. The amplified genomes are encapsulated by the L1 and L2 capsid proteins to generate infectious virions, and virus particles are observed in the granular layer of the epithelium and above. Virus assembly is not believed to lyse the cells; instead, the virus is shed with the cornified layer as cells slough from the epithelial surface (see Fig. 79.3). E4 proteins are hypothesized to disrupt the intracellular filamentous network of keratinocytes, which may facilitate virus release from the corneocytes[9].

Host Immune Response

Persistent papillomavirus infections are common, indicating that HPVs have evolved mechanisms to evade immune surveillance. There is no viremic phase during the life cycle, so a systemic immune response is avoided. In addition, low levels of viral proteins are expressed in the basal and spinous cell layers of the epidermis, where they would be most likely to be recognized by Langerhans cells and infiltrating lymphocytes. Only in the more immunologically privileged terminally differentiated layers is there extensive production of virion proteins, with shedding of infectious virus exclusively from the external epithelial surface[9]. Despite the relative success of papillomaviruses in evading immune responses, up to two-thirds of cutaneous warts spontaneously regress within 2 years, and lesions of multifocal infections often regress concomitantly. There is also an increased prevalence of warts in patients with suppressed cell-mediated immunity. In contrast, patients with underlying defects in humoral immunity do not seem to be predisposed to HPV infections, suggesting a primary role of cell-mediated responses.

Although low amounts of virion capsid proteins are produced in the lower epidermal cell layers, serum antibodies specific to conformational virion epitopes of high-risk HPV-16 can be detected in more than half of women with low-grade or asymptomatic genital HPV-16 infections[33]. It is unknown if these antibodies play a role in limiting reinfection with the same type from autoinoculation or from an infected sexual partner.

Latent HPV infections are defined as persistence of HPV DNA in clinically and cytologically normal epithelium. However, it is difficult to distinguish true viral latency from persistent infection with a low level of DNA replication. The mechanisms by which HPV enters into and is activated out of latency are unknown[9].

Oncogenic Potential of HPV

Different HPV types have markedly different oncogenic potentials. The vast majority of cervical cancers, for example, contain the sequences of one of five HPV types: 16, 18, 31, 33, or 45[34]. In contrast, infection with HPV-6 or -11 occurs commonly in benign or low-grade intraepithelial lesions but is very rarely associated with the development of anogenital malignancies. HPV-5 and -8 DNA sequences are frequently detected in SCCs associated with EV.

Progression of HPV-associated cervical lesions to invasive cancer typically requires several decades. Both persistent HPV infection and the accumulation of additional genetic mutations are required in the current model of multistage carcinogenesis[9]. Integration of the viral genome randomly into the host DNA is a common event, invariably leading to loss of E1 and E2 expression. In HPV-16 and -18, E2 functions to repress the transcription of E6 and E7 genes. Therefore, integration is thought to increase expression of E6 and E7, which are selectively retained and expressed at elevated levels in carcinomas, suggesting a critical role for oncogenic progression (see above)[9].

Differences in the activities of E6 and E7 genes between oncogenic and non-oncogenic HPV types principally account for the different risk of progression. E6 and E7 proteins derived from high-risk HPV types (e.g. 16 and 18) degrade p53 and interact with RB (respectively) with greater efficiency than do E6 and E7 proteins from low-risk types (e.g. 6 and 11)[9]. Degradation of p53 by E6, which eliminates from infected cells the principal "guardian of the genome" (the protein responsible for cell cycle arrest in the presence of damage to cellular DNA), can lead to the accumulation of genetic mutations in infected cells. Thus, carcinogenic progression appears to be promoted or facilitated by increased E6 and E7 expression as well as by activity of external carcinogens, resulting in genomic instability[9].

CLINICAL FEATURES

Cutaneous and mucosal HPV types form two distinct groups that infect either skin or mucosa. However, viral tropism is not absolute, as DNA of skin types may be found in genital or oral warts, and in rare cases, mucosal types may be associated with skin lesions. Clinical manifestations depend on the HPV type involved, the anatomic location, and the immune status of the host (Table 79.1).

Cutaneous Infections

Cutaneous HPV types comprise a small group of viruses that infect the skin and induce common warts (Latin *verrucae vulgares*; singular *verruca vulgaris*), palmar and plantar warts (*verrucae palmares et plantares*), mosaic warts, flat warts (*verrucae planae*), and butcher's warts (see Table 79.1). In general, classification of warts is based on morphology, histology, and anatomic location.

Common warts are hyperkeratotic, exophytic, dome-shaped papules or plaques that are typically associated with HPV-1, -2, -4, -27, or -57. These warts are most frequently located on the fingers and dorsal surfaces of the hands (Fig. 79.4 & 79.5) or in other sites prone to trauma such as the knees or elbows, but they may occur anywhere on the skin surface. Involvement of the proximal nail fold and/or ablative therapy at that location may destroy the matrix, resulting in onychodystrophy (see Fig. 79.5). Characteristic features of common warts are punctate black dots representing hemorrhage into the stratum corneum (Fig. 79.6). Autoinoculation by scratching may cause a linear arrangement of warts. Slender, exophytic filiform warts can also develop, especially in periorificial locations on the face (Fig. 79.7). Numerous verrucae can be observed in immunocompromised patients and rarely they are eruptive when the immunosuppression is drug-induced.

Palmar and plantar warts appear as thick, endophytic papules on the palms, soles, and lateral aspects of the hands and feet, with gently sloping sides and a central depression resembling an anthill (hence the term *myrmecia*, meaning anthill). On the soles, these are often painful from pressure when walking, due to their deep inward growth (Fig. 79.8). Plantar warts that coalesce into large plaques are referred to as *mosaic warts* (see Fig. 79.8). Extensive chronic verrucosis that

Downloaded for Anonymous User (n/a) at Egyptian Knowledge Bank from ClinicalKey.com by Elsevier on March 10, 2024. For personal use only. No other uses without permission. Copyright ©2024. Elsevier Inc. All rights reserved.

CLINICAL MANIFESTATIONS AND ASSOCIATED HUMAN PAPILLOMAVIRUS (HPV) TYPES		
	Frequently detected	**Less frequently detected**
Skin lesions		
• Common, palmar, plantar, myrmecial and mosaic warts	1, 2, 4, 27, 57	29, 41, 60, 63, 65
• Flat warts	3, 10	28, 29
• Butcher's warts	7	1, 2, 3, 4, 10, 28
• Digital squamous cell carcinoma and Bowen disease	16	26, 31, 33, 34, 35, 51, 52, 56, 73
• Epidermodysplasia verruciformis (EV)	3, **5**, **8**	**9**, **12**, **14**, **15**, **17**, **19–25**, **36–38**, **47**, **49**, 50, etc.
• EV – squamous cell carcinoma	**5**, **8**	**14**, **17**, **20**, **47**
• Digital papillary adenocarcinoma	42	
Mucosal lesions		
• Condylomata acuminata	6, 11	40, 42*–44, 54, 61, 70, 72, 81
• High-grade intraepithelial neoplasias (including cervical condylomata plana, bowenoid papulosis, erythroplasia of Queyrat) and invasive cancer	16	18, 26*, 31, 33, 35, 39, 45, 51, 52, 53*, 56, 58, 59, 62, 66*, 68, 73, 82
• Buschke–Löwenstein tumor	6, 11	
• Recurrent respiratory papillomatosis, conjunctival papillomas	6, 11	
• Heck disease (focal epithelial hyperplasia)	13, 32	
*Probably carcinogenic[34].		

Table 79.1 Clinical manifestations and associated human papillomavirus (HPV) types. HPV types in the genus β are in **bold**.

Fig. 79.4 Verrucae vulgares (common warts). *Courtesy A. Geusau, MD.*

Fig. 79.5 Periungual common warts. Destruction of the nail matrix and bed can lead to partial (**A**) or complete (**B**) absence of the nail plate. Bowen disease may be considered in the differential diagnosis, especially for a single, recalcitrant digital wart.

Fig. 79.6 Verrucae plantares (plantar warts). The photo was taken after shaving of the hyperkeratotic surface; the black dots represent hemorrhage into the stratum corneum.

is notoriously resistant to therapy has been observed in immunocompromised individuals, and, at times, in patients with no apparent immune dysfunction (Fig. 79.9). Inclusion warts of the sole are plantar cysts from which HPV types 4, 60, 63, and 65 have been isolated[35]. In studies from Europe, HPV-1 and the closely related types HPV-2, -27, and -57 caused the majority of palmoplantar warts, and they occurred most commonly in patients 6–10 years of age[36,37]. Although a higher incidence of HPV-2-related warts was reported in atopic children, other investigators have failed to find such an association.

Flat warts are skin-colored or pinkish to brown, relatively smooth-surfaced, slightly elevated, flat-topped papules that are most commonly located on the dorsal hands, arms, or face, often in a linear array (Fig. 79.10). They are usually caused by HPV-3 or -10, and less often by HPV-28 and -29.

Butcher's warts, which earn their name from their occurrence in meat- (or fish-) processing professionals, appear as extensive verrucous papules or cauliflower-like lesions on the dorsal, palmar, or periungual aspects of the hands and fingers. These warts are associated with HPV-7 not animal papillomaviruses.

Epidermodysplasia verruciformis (EV), first described in 1922 by Lewandowski and Lutz, is a rare genetic disease. It is characterized by a particular susceptibility to cutaneous infections with HPV types in the genus β (see above), which do not produce clinical lesions in immunocompetent individuals[38]. The disease usually manifests in childhood with highly polymorphic, widespread lesions. About two-dozen specific HPV types have been described in EV patients, a subset of which (mainly types 5 and 8) is also detected in EV-associated skin cancers. EV typically has an autosomal recessive pattern of inheritance and is caused by truncating mutations in two genes, *TMC6 (EVER1)* and

Downloaded for Anonymous User (n/a) at Egyptian Knowledge Bank from ClinicalKey.com by Elsevier on March 10, 2024. For personal use only. No other uses without permission. Copyright ©2024. Elsevier Inc. All rights reserved.

Fig. 79.7 Multiple filiform warts on the lower face.

Fig. 79.8 Myrmecial wart. The wart at the base of the distal phalanx of the hallux is painful due to deep endophytic growth; in addition, there are confluent plaques of superficial warts (mosaic warts).

Fig. 79.9 Extensive and chronic verrucosis of the soles in a patient with hepatic cirrhosis due to alcoholism. HPV-27 DNA was isolated from the lesions.

TMC8 (EVER2), that encode transmembrane proteins localized to the endoplasmic reticulum[39]. These proteins form a complex that interacts with the zinc transporter 1 (ZnT1) and affects intracellular zinc distribution, down-regulating zinc-associated transcription factors[40]. Inhibition of ZnT1-TMC6/8 function by the HPV E5 protein is thought to facilitate viral infection; β HPV types lack E5, but they become pathogenic in EV patients with TMC6/8 defects[40].

Patients with EV present with widespread, discrete, or confluent papules that resemble flat warts (Fig. 79.11A); scaly, pinkish, or hypopigmented guttate macules and thin plaques that resemble pityriasis versicolor represent another characteristic finding (Figs. 79.11B & 79.12). In an individual patient with EV, warts that appear clinically distinct often contain different HPV types, and each skin lesion usually contains several HPV types. Actinic keratoses usually arise after the age of 30 years and slowly transform into invasive SCCs in approximately half of EV patients. These tumors have low metastatic potential and develop primarily in sun-exposed areas such as the forehead, ears, and hands, implicating UV irradiation as an important co-carcinogen. Patients with EV should be educated about the importance of minimizing sun exposure, and family members should be screened for the presence of similar lesions.

It may be difficult to differentiate flat warts from EV-associated lesions based on histology alone (see below), but the presence of lesional β HPV DNA (e.g. HPV-5, -8, etc.) can establish the diagnosis in an otherwise healthy individual. Beta HPV types can also induce a sporadic EV-like eruption in immunosuppressed patients, including transplant recipients and those with AIDS or a lymphoma. Of note, efflorescence of HIV-associated acquired EV has been observed following the second dose of the quadrivalent HPV vaccine.

In addition, β HPV sequences have been isolated from the normal skin of healthy individuals by highly sensitive DNA detection methods, indicating that the general population acts as the reservoir for these HPV types. There is increasing epidemiologic and biologic evidence that β HPV types may play an adjunct role in the initiation, but not maintenance, of SCCs in immunosuppressed patients[41].

WHIM syndrome is a rare, autosomal dominant primary immunodeficiency disorder characterized by HPV-induced *w*arts (cutaneous and genital), *h*ypogammaglobulinemia, recurrent bacterial *i*nfections, and neutropenia due to *m*yelokathexis (retention of mature neutrophils in the bone marrow) (see Ch. 60). It is caused by mutations in the gene encoding the chemokine CXC receptor 4 (CXCR4), which result in impaired leukocyte trafficking and homing[42].

Several other primary immunodeficiencies are associated with severe HPV infection including DOCK8 deficiency, GATA2 deficiency (MonoMAC), hyper IgM syndrome, and idiopathic $CD4^+$ lymphopenia (see Table 60.1)[43].

Mucosal Infections

More than 40 HPV types preferentially infect the mucosa of the anogenital and upper aerodigestive tracts. Subclinical infections are much more common than visible warts. Application of 5% acetic acid (aceto-whitening) may aid in the identification of subclinical lesions as white areas.

Condylomata acuminata (singular: *condyloma acuminatum*), or anogenital warts, are found on the external genitalia and the perineum, perianally, or in adjacent areas such as the inguinal fold and mons pubis. Lesions may extend into the vagina, urethra, or anal canal (but rarely beyond the dentate line). Condylomata are typically discrete, sessile, smooth-surfaced exophytic papillomas or acuminate warts and may be skin-colored, brown, or whitish (especially when macerated in moist areas) (Fig. 79.13). They lack the thick cuirass of horny scale present on cutaneous warts and frequently measure one to several millimeters in diameter. Condylomata may also present as pedunculated or broad-based papillomas up to several centimeters in diameter or as large confluent plaques (Fig. 79.14). *Condylomata plana*, or flat cervical warts, may be difficult to recognize without aceto-whitening and the use of a (magnifying) colposcope. High-grade intraepithelial neoplasias are usually caused by high-risk types, mainly HPV-16, -18 and -31, whereas low-grade lesions may contain low-risk as well as high-risk HPV types.

Bowenoid papulosis manifests as multiple red–brown papules or confluent plaques on the external genitalia, on the perineum, or perianally (Fig. 79.15 & 79.16; see Fig. 73.13). These lesions primarily

Downloaded for Anonymous User (n/a) at Egyptian Knowledge Bank from ClinicalKey.com by Elsevier on March 10, 2024. For personal use only. No other uses without permission. Copyright ©2024. Elsevier Inc. All rights reserved.

Fig. 79.10 Verrucae planae (flat warts). Multiple skin-colored or pink (**A, B**) to brown (**C**) smooth-surfaced, flat-topped papules. (**D**) Thin pink papules and plaques that are well demarcated and have more scale than the patients in A-C. These lesions are typically caused by HPV-3 or -10. *B, Courtesy Kalman Watsky, MD; C, Courtesy Julie V. Schaffer, MD.*

Fig. 79.11 Epidermodysplasia verruciformis (EV). A Confluent scaly papules and plaques resembling flat warts. **B** Numerous hypopigmented and light pink, flat-topped papules, some of which are in a linear array, in acquired HIV-associated EV. *B, Courtesy Ncoza Dlova, MD.*

Fig. 79.12 Epidermodysplasia verruciformis. Generalized erythematous macules and plaques are seen in the same patient as shown in Fig. 79.11A. Lesions tested positive for HPV-8 and -36.

affect young adults and may clinically resemble genital warts, but histologically represent a high-grade squamous intraepithelial lesion (HSIL) or SCC *in situ*[44]. *Erythroplasia of Queyrat* is a distinct clinical entity, presenting as a well-demarcated, velvety erythematous plaque on the glabrous skin of the penis, vulva, or perianal region that histologically is an HSIL (Fig. 79.17). A biopsy is warranted for pigmented, erosive, bleeding, and/or therapy-resistant genital lesions to exclude malignancy. *Bowenoid papulosis* and *erythroplasia of Queyrat* contain high-risk HPV types, predominantly HPV-16, and may thus represent a precursor lesion of vulvar, penile, or perianal cancer. As noted above, these entities can represent variants of SCC *in situ*.

Buschke–Löwenstein tumor (giant condylomata acuminata), *oral florid papillomatosis of Ackerman* (oropharyngeal), *epithelioma cuniculatum* (plantar), and *papillomatosis cutis carcinoides of Gottron* (cutaneous) are types of "low-grade-malignant" verrucous carcinomas that have been associated with HPV infection. Verrucous carcinomas

Downloaded for Anonymous User (n/a) at Egyptian Knowledge Bank from ClinicalKey.com by Elsevier on March 10, 2024. For personal use only. No other uses without permission. Copyright ©2024. Elsevier Inc. All rights reserved.

Fig. 79.13 Condylomata acuminata. Verrucous lesions on the glans and in the sulcus, with a few small papules on the shaft of the penis and distal glans. Note the acuminate topography, i.e. the tapering to a point. *Courtesy Lorenzo Cerroni, MD.*

Fig. 79.14 Condylomata acuminata. A Confluent lesions forming hyperpigmented plaques in the perineal region and along the inguinal fold. A depigmented scar is seen at the site of prior treatment with liquid nitrogen. **B** Large, exophytic, broad-based or pedunculated papillomas in a healthy 15-year-old boy. The differential diagnosis includes Buschke-Löwenstein tumor.

Fig. 79.15 Bowenoid papulosis of the vulva with histopathologic features of vulvar intraepithelial neoplasia (VIN). Extensive red–brown or whitish papules and plaques containing high-risk mucosal HPV in an HIV-positive patient. Analogous high-grade squamous intraepithelial lesions (HSIL) were present perianally (AIN) and on the cervix (CIN).

Fig. 79.16 Bowenoid papulosis of the anus positive for high-risk mucosal HPV in a man who had sex with men. Histology revealed high-grade anal intraepithelial neoplasia (AIN), not invasive SCC. However, continued monitoring is indicated.

are locally invasive and destructive but rarely metastasize[45] (see Ch. 108). Buschke–Löwenstein tumor is a rare neoplasm of the anorectal area and external genitalia associated with the low-risk HPV types 6 or 11 that usually cause condylomata acuminata. The basis for the difference in biologic behavior between these two entities has not been established. In rare cases, pre-existing anogenital condylomata may progress into large exophytic cauliflower-like tumor masses that infiltrate deeply into underlying tissues and form fistulas and abscesses (Fig. 79.18). The histology of the Buschke–Löwenstein tumor may appear remarkably benign and resemble that of condylomata acuminata (Fig. 79.19), but its architecture is more irregular, the epithelium is more hyperplastic, and the pattern of growth is at least focally infiltrative. Focal frank malignant transformation can occur spontaneously or following X-irradiation. High-resolution imaging and a large biopsy are essential for identifying the extent of the infiltration and foci of SCC. Radical surgery may cure the disease, but recurrences are frequent, resulting in a high morbidity rate.

Oral warts appear as small, soft, pink or white, slightly elevated papules and plaques on the buccal, gingival, or labial mucosa (Fig. 79.20),

Downloaded for Anonymous User (n/a) at Egyptian Knowledge Bank from ClinicalKey.com by Elsevier on March 10, 2024. For personal use only. No other uses without permission. Copyright ©2024. Elsevier Inc. All rights reserved.

Fig. 79.17 Erythroplasia of Queyrat. A well-demarcated velvety plaque of the prepuce positive for high-risk HPV; histology revealed high-grade penile intraepithelial neoplasia (PIN).

Fig. 79.18 Giant condylomata acuminata (Buschke–Löwenstein tumor). Cauliflower-like, deeply infiltrating giant condylomata acuminata in an older woman.

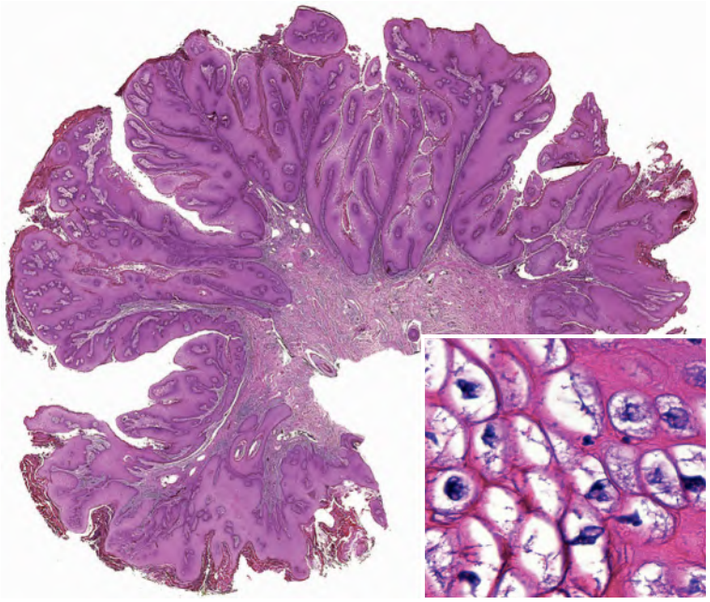

Fig. 79.19 Buschke–Löwenstein tumor – histopathologic features. Exophytic lesion with a papillomatous surface and marked, irregular epithelial hyperplasia without cellular atypia as well as the characteristic downward extension of bulbous rete ridges. Note vacuolated keratinocytes (inset). *Courtesy Luis Requena, MD.*

Fig. 79.20 Oral warts. Papillomas of the labial mucosa in a 6-year-old child.

the tongue, or the hard palate. Oral condylomata are associated with HPV types 6 and 11 and may result from digital or oral–genital sexual transmissions. In HIV-positive patients, oral papillomas are frequently detected and may contain unusual HPV types such as 7, 71, 72, and 73. In *focal epithelial hyperplasia*, or *Heck disease*, multiple circumscribed papules resembling flat warts or condylomata are found on the gingival, buccal, or labial mucosa. This disorder is rare in White individuals but relatively common in children who are native South Americans, native Greenlanders, or from South African communities. It is associated exclusively with HPV-13 or -32.

HPV (especially type 16) is a causative agent in about 25% of head and neck cancers, including the majority of oropharyngeal cancers that arise from the base of tongue and palatine tonsils. HPV-positive oropharyngeal cancers can develop irrespective of exposure to tobacco[46]. Although poorly differentiated histopathologically, they appear to have a better prognosis than HPV-negative oropharyngeal cancers whose primary risk factor is tobacco ± alcohol use[47].

In *oral florid papillomatosis*, multiple, confluent warty lesions are found in the oral cavity or the nasal sinuses. They are associated with HPV-6, -11, -16, and/or -18 in approximately half of cases. The development of these lesions is believed to be promoted by smoking, X-irradiation, and chronic inflammation. Patients with oral papillomas need frequent examinations and repeated biopsies for early diagnosis of progression to verrucous carcinoma.

In *recurrent respiratory papillomatosis* (RRP), there are benign exophytic laryngeal papillomas caused by HPV-6 and -11[28]. Patients classically present with a triad of hoarseness, stridor, and respiratory distress. Papillomas arise most often at the transition zones between the squamous and cilia-bearing epithelia of the larynx and subglottis, but they may rarely extend to the distal trachea, the bronchi, or even the bronchoalveoli. Malignant transformation of laryngeal papillomas into SCCs in patients with long-lasting disease has been reported, and exogenous factors such as X-irradiation, smoking, chemical toxins, or chemotherapy have been implicated as co-carcinogens.

PATHOLOGY

The histopathologic changes induced by HPV infection are variable, reflecting the myriad clinical presentations and different anatomic sites. In productive HPV infections, a common motif in epithelial cells

Downloaded for Anonymous User (n/a) at Egyptian Knowledge Bank from ClinicalKey.com by Elsevier on March 10, 2024. For personal use only. No other uses without permission. Copyright ©2024. Elsevier Inc. All rights reserved.

is the presence of cytoplasmic vacuoles isolating the nucleus from the cytoplasmic membrane. Cells with this distinctive vacuolization are referred to as koilocytotic (hollow) cells, and the presence of koilocytosis is a useful feature that distinguishes verrucae from other types of papillomas[48].

Common and Deep Palmoplantar Warts

Common warts are well circumscribed from the surrounding skin and characteristically have steeply sloping "church spire" papillomatosis heaped with ortho- and parakeratosis (Fig. 79.21). Parakeratosis is most commonly observed directly overlying the summits of the papillomatosis and is often accompanied by small intracorneal hemorrhages. There is also marked acanthosis and the rete ridges are elongated. In palmoplantar warts, the lateral edges of the wart bow inward to create a cup-shaped invagination below the papillomatosis. Higher-power examination reveals hypergranulosis and condensed coarse cytoplasmic keratohyalin-like granules of variable size and shape within the granular layer, along with vacuolization of cells on top of, or sometimes between, the papillae. Koilocytosis is typically observed in or immediately below the granular layer. The papillary dermis underlying the elongated rete ridges has minimal pathologic changes; increased vascularity can be observed.

Flat Warts

The characteristic features of flat warts include orthokeratosis alternating with parakeratosis, acanthosis, no or minimal papillomatosis, a uniformly thickened granular layer, and vacuolization of cells in the granular and upper spinous layers (termed "bird's eyes")[48].

Some patients with flat warts develop clinically evident inflammation around these warts, which may precede their spontaneous involution. Characteristic histologic features of regressing flat warts include parakeratosis, spongiosis, exocytosis of mononuclear cells into the lower epidermis, and (occasionally) satellite cell necrosis. By immunohistochemistry, T helper cells predominate and HLA-DR antigen, a marker of immune activation, is detected on the surface of the infiltrating lymphocytes and on some keratinocytes. Many of these changes can also be observed in regressing condylomata, suggesting that wart regression is mediated, at least in part, by a delayed-type hypersensitivity-like cellular immune response directed against keratinocytes expressing wart antigens[49].

Epidermodysplasia Verruciformis

In patients with EV, the flat warts and pityriasis versicolor-like lesions exhibit orthokeratosis with a basket-weave appearance, parakeratosis, and acanthosis. Under higher power, some cells within the hyperplastic spinous layer have characteristic cytopathic changes. These cells are large with perinuclear halos and a cytoplasm that has blue–gray pallor and contains keratohyaline granules of various sizes and shapes (Fig. 79.22). Keratinocytic dysplasia and actinic keratoses may be evident, especially in biopsies of lesions from sun-exposed areas[48]. Because the histologic picture is nonspecific, it may be difficult to differentiate typical flat warts from EV-associated lesions based on histology alone.

Anogenital Warts

The most consistent histologic features seen in condylomata include epidermal hyperplasia, parakeratosis, koilocytosis, and papillomatosis. The papillomatosis is more gently rounded than is seen in common warts. The upper portions of the epithelia of mucosal surfaces normally have some degree of cytoplasmic vacuolization, so its detection is specific for condylomata acuminata only if present within the deeper portions of the spinous layer[48]. Mitotic figures may be evident, and prior treatment with podophyllotoxin (which interferes with microtubule formation in cells undergoing mitosis) can induce the appearance of atypical mitoses that could potentially lead to misdiagnosis as SCC.

Giant Condylomata of Buschke–Löwenstein

The histology of the Buschke–Löwenstein tumor shares many features with condylomata acuminata, but there is more evident irregular epithelial hyperplasia, with marked downward extension of characteristically bulbous rete ridges, and less vacuolization of epidermal cells (see Fig. 79.19). Mitotic figures are rarely detectable, and, when present, are normal. While usually associated with extension into and destruction of local tissue, metastases to local lymph nodes from foci of SCC arising in these tumors have been reported[45].

Squamous Intraepithelial Neoplasias

Persistent infection with high-risk HPV types can lead to intraepithelial neoplasia that may progress to invasive carcinoma. The precancerous lesions represent a continuum of morphologic changes with indistinct boundaries. In CIN grade I, nuclear enlargement and hyperchromasia is observed in the lower epithelial layers; these changes may be accompanied by cytoplasmic halos (koilocytotic atypia). The next stage (CIN II) shows progressive atypia in all layers of the epithelium, with abnormal differentiation of the keratinizing cell layers. The atypical cells have an increased nuclear–cytoplasmic ratio, variability of nuclear size, and an increased number of mitotic figures, including abnormal mitoses and hyperchromasia. In CIN III, the epithelium is totally replaced by immature, atypical cells

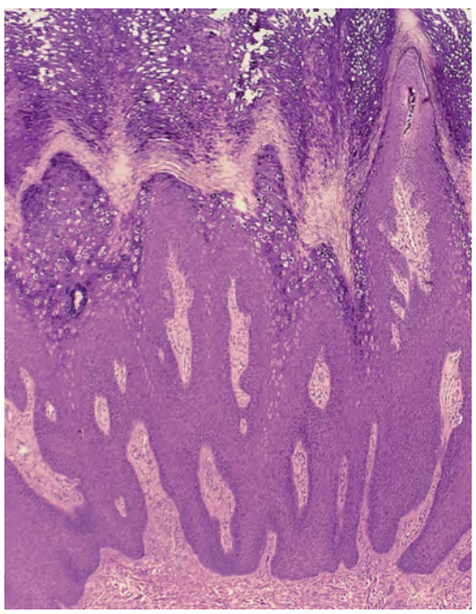

Fig. 79.21 Verruca vulgaris – histopathologic features. Note the characteristic features of "church spire" papillomatosis heaped with ortho- and parakeratosis, acanthosis, hypergranulosis, and koilocytosis. *Courtesy R. Tyler, MD.*

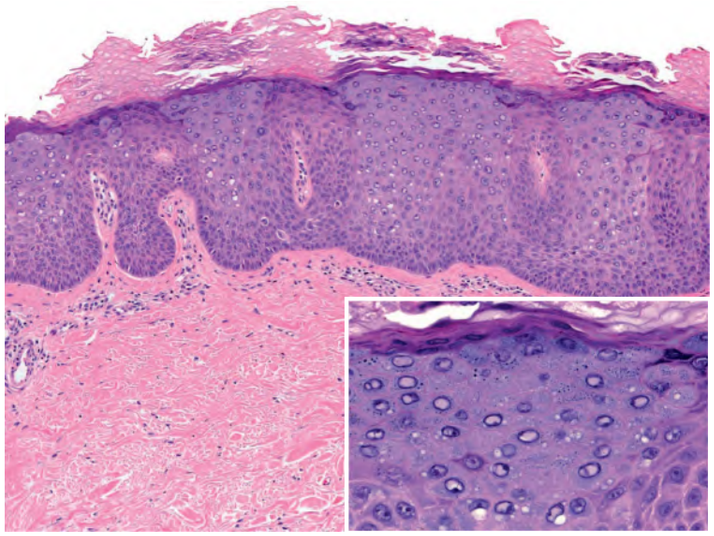

Fig. 79.22 Epidermodysplasia verruciformis – histopathologic features. Orthokeratosis alternating with parakeratosis and acanthosis are present. Note the cells with blue–gray, granular cytoplasm in the mid to upper epidermis (inset). *Courtesy Lorenzo Cerroni, MD.*

Downloaded for Anonymous User (n/a) at Egyptian Knowledge Bank from ClinicalKey.com by Elsevier on March 10, 2024. For personal use only. No other uses without permission. Copyright ©2024. Elsevier Inc. All rights reserved.

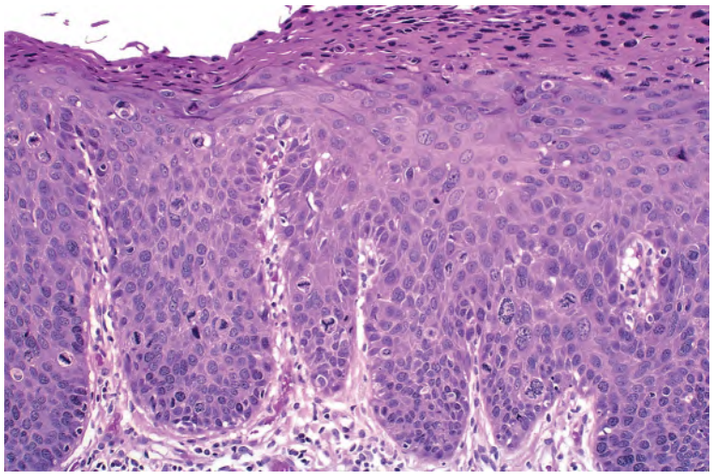

Fig. 79.23 Vulvar intraepithelial neoplasia (VIN) – histopathologic features. Note the characteristic features of abnormal keratinocyte maturation, nuclear pleomorphism, and dyskeratosis. Koilocytosis, due to cytoplasmic vacuoles that isolate the nucleus from the cytoplasmic membrane, can be observed in or immediately below the granular layer. Some pathologists refer to these intraepithelial neoplasias as SCC *in situ*. *Courtesy R. Tyler, MD.*

with a lack of surface differentiation. The analogous lesions of the vulva, vagina, penis, and anus are termed VIN (vulvar intraepithelial neoplasia; Fig. 79.23), VaIN (vaginal intraepithelial neoplasia), PIN or PeIN (penile intraepithelial neoplasia), and AIN (anal intraepithelial neoplasia), respectively. Clinically, these may appear as erythematous or whitish plaques (erythroplasia, leukoplakia) or red–brown papules (bowenoid papulosis) (see Figs. 79.15–79.17). Terminology of these lesions remains a matter of debate, and many pathologists refer to these "intraepithelial neoplasias" as "SCC *in situ*".

DIFFERENTIAL DIAGNOSIS

The diagnosis of cutaneous and genital warts is straightforward if typical clinical features are present. Occasionally, various other diagnoses have to be considered and a biopsy may be required for confirmation and to identify dysplastic lesions. Immunohistochemistry with antibodies directed against cross-reacting epitopes of papillomavirus capsid proteins allows the detection of virions in palmoplantar warts, which are highly productive infections, but has limited sensitivity in genital warts and dysplasias. There is no routine infectivity assay available to detect virions in clinical samples, and diagnostic tests are therefore based on the molecular detection of papillomavirus DNA. Commercially available tests that utilize nucleic acid hybridization (e.g. *digene* Hybrid Capture® 2 [HC2] HPV DNA Test; Amplicor® HPV and Linear Array® HPV Genotyping Test, Roche [not available in the US]) can identify low-risk versus high-risk mucosal HPV types in clinical samples with high sensitivity and specificity. In routinely processed histologic sections, RNA *in situ* hybridization can also be performed utilizing pooled high-risk versus low-risk HPV subtypes. In addition, PCR-based techniques can detect a broad range of genital and skin HPV types[50,51]. Development of circulating antibodies against the L1 major capsid protein is common following infection with genital HPV types, and ELISAs using L1 VLPs as the antigen have been useful in epidemiologic studies[33]. However, due to low antibody titers and variable intervals between infection and seroconversion, this assay is not used for diagnosis in individual patients.

Common, Flat, and Palmoplantar Warts

Seborrheic keratoses (SKs), actinic keratoses (AKs), cutaneous horns (which can arise from warts as well as AKs, SCCs, SKs, and other neoplasms; see Ch. 109), keratoacanthomas, other SCCs, tricholemmomas, Spitz nevi, and amelanotic melanomas may resemble *common warts*, and even tuberculosis verrucosa cutis or a plaque of psoriasis, hypertrophic lichen planus, hypertrophic lupus erythematosus, or pseudoepitheliomatous tattoo reaction can have a warty clinical appearance. On the distal or lateral finger or periungually, a wart-like or erythematous, well-demarcated plaque may occasionally represent Bowen disease and harbor high-risk HPV types, e.g. 16 or 18. Similarly, amelanotic melanoma can masquerade as a persistent periungual or plantar wart and should be clinically suspected if erosion or subtle pigmentation is present. The differential diagnosis of *flat warts* may include acrokeratosis verruciformis, Gottron papules of dermatomyositis (distinguished by their localization over the knuckles), lichen nitidus, lichen planus, and lichenoid keratoses. Although lesions of both lichen planus and flat warts can have a linear array, the presence of Wickham striae points to the former diagnosis. Plantar clavi (corns) are often misdiagnosed as warts, although verruca can be differentiated by the presence of punctate black dots rather than a glassy appearance; in addition, paring of the keratotic wart surface leads to capillary bleeding from the superficially located dermal papillae. Punctate palmoplantar keratoderma, punctate porokeratosis, arsenical keratoses, poromas, and eccrine poromatosis can mimic plantar warts.

In patients with cellular immunodeficiencies, including organ transplant recipients and those with AIDS or hematologic malignancies, the number as well as incidence of cutaneous and genital warts is increased. Warts that appear at less common sites such as the face and the neck need to be differentiated from mollusca contagiosa. In immunosuppressed patients, macular and flat warts may resemble EV, but the clinical setting and absence of a family history can aid in establishing the correct diagnosis. Other heritable immunodeficiencies that predispose affected individuals to the development of warts include WHIM syndrome (see above), idiopathic $CD4^+$ lymphopenia, DOCK8 deficiency, hyper IgM syndrome, PI3Kδ syndrome, and GATA2 deficiency (MonoMAC) (see Ch. 60 & Table 60.1)[43].

Anogenital Lesions

Condylomata acuminata are rarely confused with condylomata lata of secondary syphilis, but serologic testing for syphilis (and, as indicated, other STIs) is recommended in patients with genital warts, and dark-field examination for spirochetes may be considered. Mollusca contagiosa preferentially involve the mons pubis and can be distinguished by their umbilication, with dermoscopy revealing a multilobular, yellow–white central structure surrounded by a "crown" of vessels. In men, pearly penile papules are normal anatomic structures consisting of several rows of discrete, monomorphic, dome-shaped, 1 to 2 mm papules circumferentially around the corona and/or sulcus of the glans penis (see Ch. 116). An analogous picture exists in women, called vestibular papillomatosis, with tiny, uniformly shaped, finger-like projections at the introitus and on the labia minora. Sebaceous glands of the prepuce and labia majora appear as white–gray to yellow, small papules with a regular array. Epidermoid cysts, steatocystomas, or angiokeratomas of the scrotum seldom pose diagnostic problems. Occasionally, verrucous herpetic infections may mimic genital warts.

Detection of subclinical genital HPV infection is facilitated by soaking with 5% acetic acid for 3 to 5 minutes; this leads to whitening ("aceto-whitening") of lesions, and the use of a colposcope for magnification will further increase diagnostic accuracy. However, aceto-whitening is not specific for HPV-induced lesions and is also observed in infectious or inflammatory conditions such as *Candida* vulvitis or balanoposthitis, psoriasis, lichen planus, and eczematous dermatitis.

Bowenoid papulosis consists of red–brown papules or confluent, sometimes leukoplakia-like plaques that may be difficult to distinguish from condylomata (see Fig. 79.15 & 79.16 and Ch. 73). *Erythroplasia of Queyrat* is a well-defined, velvety, erythematous plaque of the glans or vulva that must be differentiated from erosive lichen planus and Zoon balanitis. *Bowen disease* can present as a solitary patch or plaque, sometimes scaly, of the vulva or penis, most often in older individuals. *Extramammary Paget disease* appears as a well-defined red plaque in the groin or pubic region or on the vulva, penile root, or perianal skin, with distinctive histopathologic features (see Ch. 73).

Vulvar carcinomas are etiologically heterogeneous. Carcinomas with basaloid or warty histology are related to HPV infection, whereas keratinizing squamous carcinomas are not[52]. Basaloid and warty vulvar carcinomas typically arise in younger women, are found adjacent to vulvar intraepithelial neoplasia (VIN; also referred to as high-grade squamous intraepithelial lesion [HSIL]), and are associated with risk factors related to sexual practices. Close to 90% of high-grade VIN/HSIL and basaloid and warty vulvar carcinomas contain high-risk HPV DNA

Downloaded for Anonymous User (n/a) at Egyptian Knowledge Bank from ClinicalKey.com by Elsevier on March 10, 2024. For personal use only. No other uses without permission. Copyright ©2024. Elsevier Inc. All rights reserved.

Fig. 79.24 Invasive squamous cell carcinoma of the penis. It developed over more than a decade from a papular lesion of the prepuce. HPV-16 and -51 DNAs were detected by RT-PCR.

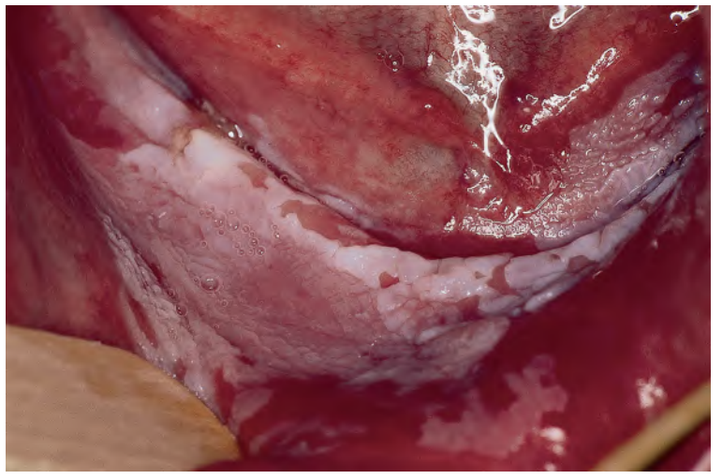

Fig. 79.25 Proliferative verrucous leukoplakia of the oral cavity. The lesions have focally progressed to invasive squamous cell carcinoma; HPV DNA was not detectable by PCR.

(most often HPV-16, but also HPV-31 and -33), suggesting a common etiology. In contrast, the more common keratinizing vulvar carcinomas in older women, which typically arise adjacent to lichen sclerosus and differentiated VIN, infrequently contain HPV DNA and thus are regarded as a distinct entity[53].

Although there is heterogeneity in anal SCC[53,54], in both sexes, the vast majority of anal cancers are attributable to HPV infection. Cancers of the anal canal that are positive for high-risk HPV (mostly HPV-16, but also HPV-18, -31, -33) tend to occur in younger men (especially MSM) and women with high-risk sexual behaviors, have basaloid histology, and arise adjacent to AIN. In contrast, HPV-negative anal cancers usually affect older men, are well keratinized, and arise from perianal skin without AIN. Heterogeneous etiology has also been described for penile cancer (Fig. 79.24), analogous to that observed for vulvar and anal SCCs[53]. Immunosuppression and a history of HPV-associated malignancy are notable risk factors for the development of a (second) anogenital cancer attributable to HPV.

Anogenital warts in children may give rise to suspicion of sexual abuse (see Ch. 90). Findings that make non-abusive transmission of HPV more likely include age <3 years, wart location somewhat distant from the anus or vulva, genital condylomata in the mother, and an absence of signs of physical abuse or of other sexually transmitted infections[17].

Giant condyloma acuminatum, or Buschke–Löwenstein tumor, is clinically suspected by its size and the presence of fistulas or abscesses (see Fig. 79.18). Histologic findings may be bland, and distinction from large benign genital warts can therefore be difficult at an early stage (see Fig. 79.19)[45,55]. However, high-resolution imaging reveals the extent of infiltration, and a large biopsy with serial sectioning may detect locally destructive growth and, rarely, transformed foci of SCC.

Oral Warts

Oral warts or condylomata may resemble the papules of focal epithelial hyperplasia (Heck disease); the latter is very rare in White individuals. A distinct oral condition with the descriptive name "proliferative verrucous leukoplakia" is clinically similar to oral florid papillomatosis but does not contain HPV DNA and has a high risk of progression to oral SCC (Fig. 79.25)[56]. Additional diagnostic considerations may include leukoedema (grayish-white translucent plaques, sometimes with a "moth-eaten" appearance, that favor the buccal mucosa and may become less evident upon stretching), white sponge nevus, and hereditary benign epithelial dyskeratosis.

MANAGEMENT OF ANOGENITAL WARTS WITH GRADING OF RECOMMENDATIONS
Patient-applied therapy (avoiding non-involved skin)
• Podophyllotoxin 0.5% solution, 0.5% gel, 0.15% cream* [BID for 3 days then discontinue for 4 days, up to 4 treatment cycles; ≤10 cm^2] (1) • Imiquimod 5% cream [6–10 hours 3 times/week, up to 16 weeks] (1) • Imiquimod 3.75% cream [once daily, up to 8 weeks] (1) • Sinecatechins 10%* or 15% ointment [TID, up to 16 weeks] (1)†
In-office therapies
• Cryotherapy (liquid nitrogen spray, cryoprobe) (1) • Trichloroacetic acid (TCA) or bichloroacetic acid (BCA) 80%–90% solution (1) • Electrosurgery (1) • Scissor or shave excision, curettage (1) • Laser vaporization (CO_2, PDL, Nd:YAG) (2) • Surgical excision (3)
Other considerations
When external anal or perianal warts are present, the possibility of intra-anal warts should be excluded, e.g. by anoscopy
*Not FDA-approved; available outside the USA. †Might weaken condoms and vaginal diaphragms.

Table 79.2 Management of anogenital warts with grading of recommendations. Based upon cases series, additional therapies include 5-fluorouracil 5% cream, topical (1%–3%) or intralesional (15 mg/ml) cidofovir, and photodynamic therapy. Key to evidence-based support: (1) prospective controlled trial; (2) retrospective study or large case series; (3) small case series or individual case reports[58,83]. PDL, pulsed dye laser. BID, twice daily; TID, three times daily.

THERAPY

General Considerations

There is currently no specific antiviral therapy available to cure HPV infection. Existing modalities focus primarily on the destruction or removal of visible lesions or induction of cytotoxicity against infected cells (Table 79.2). Because of the benign and self-limited nature of warts, treatments that cause scarring should be avoided. There is no evidence that aggressive treatment results in a better long-term outcome, and temporary interruption of therapy is an option. Common warts often regress spontaneously in children and therefore may not require treatment. A simplified algorithm for the approach to treatment of cutaneous warts is presented in Fig. 79.26.

Genital warts may be disfiguring and pose a significant psychological burden. HPV infection is typically widespread and multifocal throughout the anogenital tract, and subclinical lesions are often present. Thus, regardless of the applied therapeutic modality, reported recurrence rates are high (25%–65%) and it is unproven whether treatment reduces

Downloaded for Anonymous User (n/a) at Egyptian Knowledge Bank from ClinicalKey.com by Elsevier on March 10, 2024. For personal use only. No other uses without permission. Copyright ©2024. Elsevier Inc. All rights reserved.

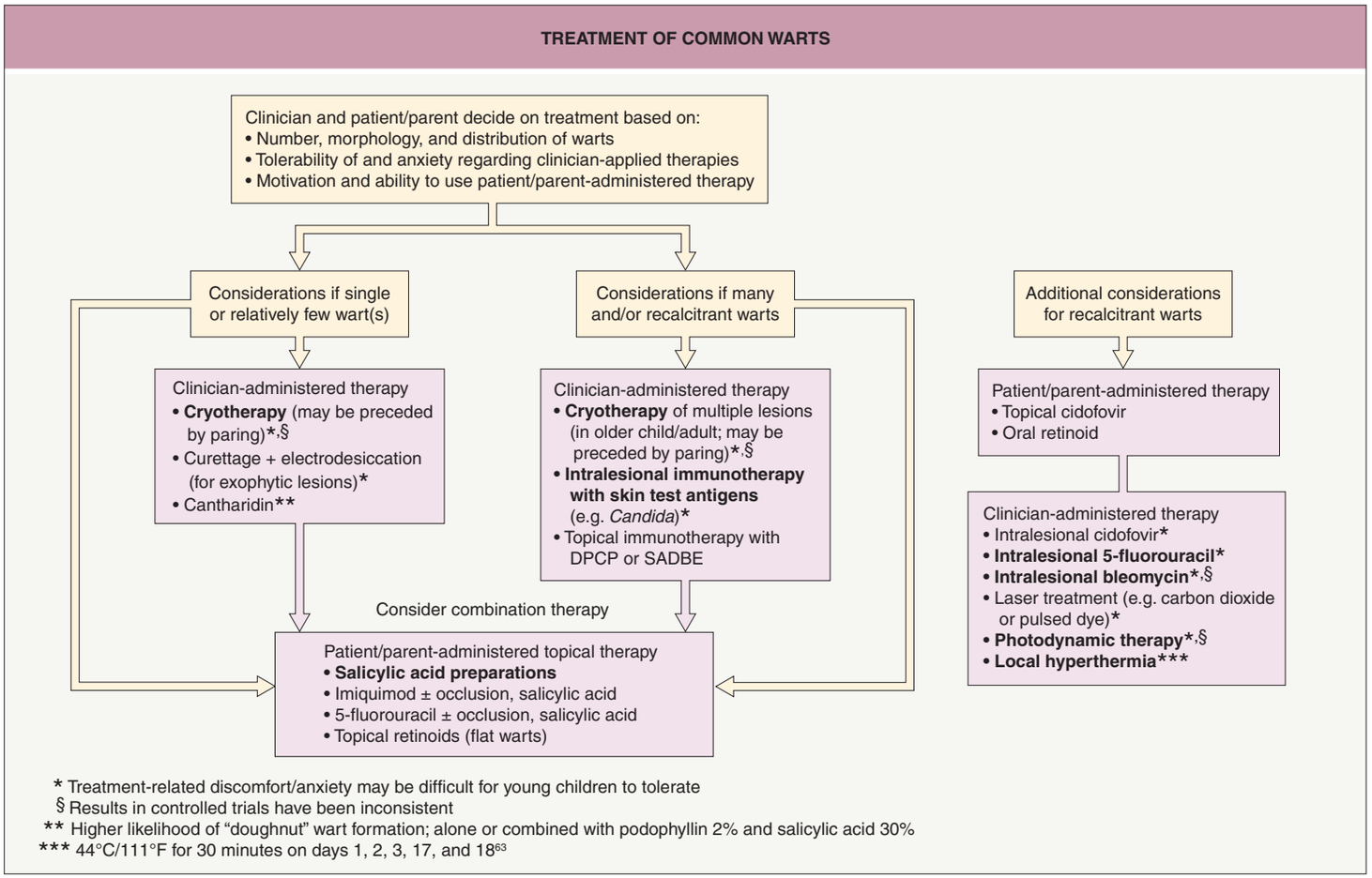

Fig. 79.26 Treatment of common warts. Therapies found to be effective in controlled trials are in **bold**. While still employed by some clinicians, three double-blind, placebo-controlled trials failed to confirm efficacy of cimetidine therapy for recalcitrant common warts. Topically, cidofovir is incorporated into an ointment, cream, or gel base at 1%–3% and intralesional cidofovir is diluted to 15 mg/ml saline. DPCP, diphenylcyclopropenone; SADBE, squaric acid dibutyl ester.

transmission rates to new sexual partners. Limiting the number of partners remains the mainstay of decreasing transmission. Condom use may also be helpful, and it has promoted regression of flat penile lesions and CIN as well as clearance of HPV in couples infected with the same HPV type[57]. Treatment is time-consuming, uncomfortable, and limited to visible warts and intraepithelial neoplasias with a high risk of progression. A simplified treatment algorithm is shown in Fig. 79.27. Current therapies for genital warts are summarized in Table 79.2 and include destructive, antiproliferative, and immunomodulatory modalities[58,59].

Local Destructive Therapy

Recommended destructive or ablative therapies for *genital warts* include cryotherapy, trichloroacetic acid (TCA) or bichloroacetic acid (BCA), electrosurgery, scissor or shave excision, curettage, laser vaporization, or excisional surgery. When anesthesia is required, topical application or injection of a local agent is usually sufficient (see Ch. 143), although general anesthesia may be indicated for surgical debulking of large lesions and occasionally in children. Ablative laser therapy is also useful for vaginal, vulvar, or anal intraepithelial neoplasias. Precautions should be taken to avoid inhalation of virus particles in the aerosol plume when laser or electrosurgical procedures are performed. Application of TCA 80%–90% solution is a commonly utilized office-applied therapy that results in local tissue destruction. Although scarring may occur following dermal injury, TCA has the advantage of a complete lack of systemic toxicity and it can be used during pregnancy.

Cryotherapy with liquid nitrogen is inexpensive, effective, safe during pregnancy, and usually does not require anesthesia; as a result, it is often used as a first-line in-office therapy for genital warts followed by patient-applied podophyllotoxin or imiquimod (see Table 79.2). Liquid nitrogen is applied with a cotton swab, spray gun, or closed system cryoprobe (see Ch. 138). Two freeze–thaw cycles, the extent of which is visually controlled, lead to wart necrosis and sometimes blistering. Multiple treatment sessions result in remission rates of 75% to 85%, with recurrences in 20%–40% of patients.

Cutaneous warts may be treated by daily application of salicylic acid/lactic acid/collodion (1 : 1 : 4), if possible with occlusion and after removing the thickened stratum corneum, or other salicylic acid preparations for 3–4 months; this results in regression in two-thirds of patients. Application of petrolatum to the surrounding normal skin protects against the corrosive effect of the concentrated acid. Weight pressure causes deep inward growth of plantar warts (myrmecia), and the resulting pain can be reduced by repeated shaving of the hyperkeratotic surface to a level at which capillary bleeding occurs. Cryotherapy with liquid nitrogen (see above) may be utilized for persistent or recurrent verrucae, including periungual lesions, with cure rates similar to or better than salicylic acid preparations in randomized controlled studies[60–64]. Other in-office or at-home freezing products (e.g. those containing dimethyl ether and propane) are less effective. Either cryotherapy that does not include a rim of surrounding skin or topical application of the blistering agent cantharidin (0.7% or 1%) may produce a "doughnut wart" due to clearance in the center but not at the periphery of the lesion. Additional destructive modalities include curettage or scissor excision (especially for filiform warts and other exophytic lesions), electrosurgery (see Ch. 140), and laser treatment (e.g. with CO_2, Nd:YAG, or pulsed dye lasers). Combination therapy with the application of topical agents following destruction may reduce the rate of recurrence.

Topical and Intralesional Cytotoxic Therapy

Podophyllin is a crude resin extract from the roots of the May apple *Podophyllum peltatum* (North America) or *Podophyllum emodi*

Downloaded for Anonymous User (n/a) at Egyptian Knowledge Bank from ClinicalKey.com by Elsevier on March 10, 2024. For personal use only. No other uses without permission. Copyright ©2024. Elsevier Inc. All rights reserved.

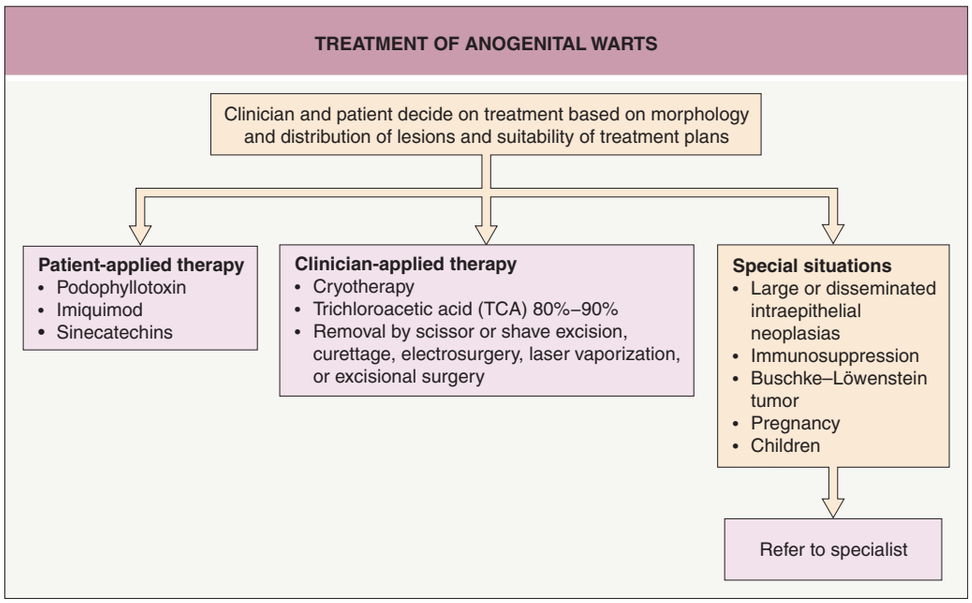

Fig. 79.27 Treatment of anogenital warts. See Table 79.2 for details of patient-applied therapies. TCA, trichloroacetic acid.

(Far East) that has been used since the early 1940s for the treatment of genital warts. Systemic toxicity can occur when applied in large volumes, and death, intrauterine demise, and teratogenicity have been reported. Because of low efficacy and potential toxicity, podophyllin use is no longer recommended[57]. Podophyllotoxin has been identified as the most active constituent of podophyllin. A regimen of patient self-applied podophyllotoxin 0.5% solution or gel twice a day for 3 days repeated in weekly cycles was shown to be effective and without evidence of systemic absorption and toxicity (see Table 79.2). Erythema and erosions are the most common side effects. In a recent network meta-analysis, podophyllotoxin 0.5% solution was significantly more efficacious than imiquimod 5% cream in clearing genital warts in non-immunocompromised patients, but the former had more adverse side effects[65]. Both podophyllin and podophyllotoxin are contraindicated during pregnancy.

Warts of the urethral meatus and urethra are difficult to manage, and stenosis and stricture due to therapy are potentially serious complications. 5-Fluorouracil (5-FU) 5% cream can be applied twice a week to treat intraurethral condylomata or, as an alternative to destructive treatments, intraepithelial neoplasias of the external genitalia. However, its use in the genital area is limited by inflammatory side effects. Successful treatment of cutaneous warts with 5-FU 5% cream applied daily under occlusion or together with salicylic acid has also been described in children and adults[66], and effective therapy with intralesional 5-FU has been reported.

Intralesional bleomycin is occasionally used to treat recalcitrant cutaneous warts, but injections are painful and may result in excessive cutaneous necrosis.

Topical Immunomodifiers

Imiquimod is an imidazoquinoline compound with immunomodulatory activities that has been approved by the US Food and Drug Administration (FDA) for the topical treatment of condylomata acuminata. Imiquimod has been shown to interact with Toll-like receptors 7 and (to a lesser degree) 8, resulting in activation of cytokine secretion from monocytes/macrophages (including interferon-α, interleukin-12, and tumor necrosis factor) as well as stimulation of antigen-presenting dendritic cells (see Ch. 128).

In an initial randomized, double-blind, placebo-controlled clinical trial, complete clearance of *genital warts* occurred in 50% of patients treated with imiquimod 5% cream compared to 11% of those treated with vehicle control; recurrence rates were low (<15%) in both groups[67]. Response rates were higher for warts on mucosal sites (i.e. female and uncircumcised male patients) than for lesions on the penile shaft or suprapubic area, suggesting the importance of crossing the stratum corneum barrier for effective treatment. Later studies confirmed the therapeutic effect of imiquimod for anogenital warts and documented that this treatment resulted in a reduction of viral load, presumably due to activation of cellular immune responses. A direct comparison of imiquimod and cryotherapy for genital warts found an earlier response with imiquimod, slightly higher efficacy with cryotherapy, and similar recurrence rates[68]. In clinical practice, destruction of genital warts by the physician, followed by patient-applied imiquimod (often requiring several cycles) is favorable over either modality alone[69]. Imiquimod has also been incorporated into suppositories and applied via anal tampons to prevent recurrence of anal condylomata following surgical ablation, or as primary treatment for anal condylomata and AIN in order to avoid the risk of scarring and stenosis of the anal canal associated with surgical procedures[70].

Therapeutic efficacy of imiquimod 5% cream has also been described for *persistent cutaneous warts*. In a controlled study (right versus left comparison) involving 14 immunosuppressed patients with recalcitrant warts on their hands and/or feet, a 36% response rate was observed for warts treated with imiquimod (three times weekly for 8 weeks, daily for 8 weeks, then daily with occlusion for 8 weeks) compared to 7% for untreated warts[71]. Improvement of common and flat warts with imiquimod therapy (daily application; ± occlusion for common warts) has also been reported in uncontrolled studies in immunocompetent patients[72]. Occlusion and/or concurrent use of salicylic acid or cryotherapy may increase imiquimod's penetration through the stratum corneum, which is especially important in acral sites.

Side effects of imiquimod include application site reactions (inflammation, erosion) that may require treatment-free periods. Imiquimod therapy is often more costly than other treatment options.

Sinecatechins 15% ointment, which contains green tea leaf-derived catechins thought to have immunostimulatory and antiproliferative properties, is approved as a topical treatment for anogenital warts. In randomized double-blind clinical studies, application of this product three times daily for up to 16 weeks led to complete clearance of anogenital warts in ~55% of patients (with frequent local irritation), compared to 35% of those treated with a vehicle control[73].

Systemic Immunomodifiers

Interferons have been used topically, intralesionally, and systemically for genital warts in controlled trials and have failed to demonstrate consistent efficacy. Systemic therapy, which is expensive and causes dose-related toxic side effects, is therefore not recommended for routine clinical use. However, interferons may be helpful as an adjunct or salvage therapy in selected patients[55]. More recently, low-dose pomalidomide was reported to clear or improve HPV-associated anal HSIL.

Immunotherapy

Increasing evidence that cellular immune responses play a critical role in wart clearance has inspired the development of topical and intralesional

Downloaded for Anonymous User (n/a) at Egyptian Knowledge Bank from ClinicalKey.com by Elsevier on March 10, 2024. For personal use only. No other uses without permission. Copyright ©2024. Elsevier Inc. All rights reserved.

immunotherapy regimens for patients with multiple and/or recalcitrant warts. In a large uncontrolled study[74], 154 children and adults with recalcitrant palmoplantar warts underwent successful topical sensitization with 2% diphenylcyclopropenone (DPCP) followed by at least six applications of 0.5%–4% DPCP to their warts at 3-week intervals. An 88% complete clearance rate was observed after an average of 6 months, with only local side effects (pruritus, blistering, eczematous reactions). Similar clearance rates have been reported for other contact sensitizers such as squaric acid dibutyl ester (SADBE), with application frequencies ranging from daily to monthly (often twice weekly), and regression of distant untreated warts has also been described.

Intralesional injection of *Candida*, *Trichophyton*, and/or mumps skin test antigens represents another approach to immunotherapy for warts in immunocompetent adults and children. In a randomized controlled clinical trial, a significantly higher clearance rate for treated as well as distant untreated common warts was observed in patients receiving intralesional antigen as compared to placebo at 3-week intervals for a total of up to five treatments (60% versus 22%, and 41% versus 19%, respectively)[75]. Effective treatment of flat warts and anogenital warts with topical and intralesional immunotherapy has also been described.

Antiviral Agents

Cidofovir is an acyclic nucleoside phosphonate with broad-spectrum activity against DNA viruses, including HSV and molluscum contagiosum, and it is approved for the systemic treatment of cytomegalovirus retinitis in AIDS patients. Although limited by the potential for renal toxicity, systemic treatment with cidofovir has shown efficacy in patients with HPV-associated lesions, including extensive cutaneous warts and severe RRP with pulmonary involvement. Intralesional injection of cidofovir (15 mg/ml saline) and topical application of 1%–3% cidofovir incorporated into an ointment, cream, or gel base have been successfully used in multiple case series of immunocompetent or immunosuppressed (e.g. HIV-infected) patients with cutaneous warts, condylomata acuminata, intraepithelial neoplasias, or RRP[76,77].

Retinoids

The effects of retinoids on keratinocyte differentiation and proliferation may lead to inhibition of HPV replication and assembly. Reduction in the bulk of extensive cutaneous or genital warts with oral retinoid therapy (e.g. acitretin, isotretinoin) has been reported in immunocompetent and immunosuppressed patients[78,79]. Successful treatment of flat warts with topical tretinoin or tazarotene has also been described.

Anti-PD-1/PD-L1 Antibodies

The aggressive nature of HPV-associated carcinomas is in part due to their ability to evade immunosurveillance via the expression of immune checkpoint molecules such as programmed cell death-ligand 1 (PD-L1), which interacts with its receptor (PD-1) on tumor-specific T cells and limits the latter's antitumor activity (Fig. 128.9)[80]. Increased levels of PD-L1 have been found in HPV-related cervical and head and neck SCCs and may play a critical role in the growth, progression, and metastases of these tumors. For example, expression of PD-L1 has been reported in 35%–95% of cervical carcinomas[81]. In several clinical trials of cervical or head and neck SCCs treated with anti-PD-1/PD-L1 antibodies, increased objective response rates and progression-free survival were observed when patients were stratified for HPV status and PD-L1 expression[82]. As a result, the FDA approved pembrolizumab in combination with chemotherapy for persistent, recurrent, or metastatic cervical cancer whose tumors express PD-L1. Pembrolizumab is also approved as a single agent for metastatic or unresectable recurrent head and neck SCCs that express PD-L1.

Special Considerations, Including Intraepithelial Neoplasias and Pregnancy

Early diagnosis of Buschke–Löwenstein tumor and other verrucous carcinomas is important to allow wide excision with clear resection margins. Surgery is the only established treatment that may cure the disease, although recurrence rates are high and the tumor can ultimately result in death. Cytotoxic chemotherapy and injections of interferon-α have led to remissions or cure in individual patients[45,55]. Whether anti-PD-1/PD-L1 antibodies could play a therapeutic role remains to be determined.

In transplant recipients and HIV-infected patients, skin and genital warts tend to resist standard treatment modalities. A surgical approach followed by non-invasive treatment of recurrent warts may be appropriate. In placebo-controlled studies, local application of imiquimod reduced genital wart area by more than 50% in 38% of HIV-infected patients. Imiquimod cream has also been used for VIN while imiquimod incorporated into suppositories or applied via anal tampons has been used for AIN, supporting a role for cellular immune enhancement for treatment of HPV-induced neoplasia.

During *pregnancy*, genital warts can increase in size and destructive procedures including surgery, cryotherapy, TCA application, and laser treatments are appropriate for removing lesions, which may theoretically reduce the risk for the newborn to acquire RRP[28]. However, this assumption is not proven and the presence of condylomata is not an indication for delivery by cesarean section. Podophyllin and podophyllotoxin are teratogenic and thus must not be used in pregnant women.

The treatment of intraepithelial neoplasias (bowenoid papulosis, erythroplasia of Queyrat, Bowen disease) is generally more aggressive than that of benign condylomata[83]. Prior to therapy, an aiming biopsy (e.g. colposcopically directed) is always required to exclude (micro) invasion histologically. For patients with bowenoid papulosis and erythroplasia who are younger than 45 years of age, superficial destruction of lesions (e.g. with cryotherapy or laser vaporization) may be appropriate to avoid mutilation[84]. In immunocompetent patients less than 35 years of age, bowenoid papulosis is regarded as a benign and self-limited disease[85]. Nevertheless, prolonged observation appears mandatory to detect recurrences.

HPV VACCINES

Three decades ago, recombinant DNA technology was used to generate a prophylactic subunit vaccine that consists of the L1 major capsid protein, which self-assembles into empty capsids designated as virus-like particles (VLPs) (see Fig. 79.1)[3]. VLPs resemble native virions morphologically and immunologically, and they carry neutralization epitopes on their surface. However, as a safety advantage, VLPs do not contain potentially oncogenic viral DNA and cannot replicate. Systemic immunizations with VLPs induce high-titer, long-lasting, and type-restricted neutralizing antibodies[4,86].

Prophylactic vaccinations in several animal models of papillomavirus infection were spectacularly successful in preventing natural or experimental infection of skin and mucosa[2,87]. In phase I/II human trials, systemic immunizations with VLP-based vaccines were non-toxic and highly immunogenic, inducing robust neutralizing antibody responses[86]. Based on these promising results, large-scale prophylactic vaccination trials were conducted to evaluate the safety and efficacy of two agents in preventing genital HPV infection and associated lesions in young women: (1) a quadrivalent vaccine of HPV-6, -11, -16, -18 VLPs (Gardasil®; Merck); and (2) a bivalent vaccine of HPV-16, -18 VLPs (Cervarix®; GlaxoSmithKline). Study endpoints were detection of HPV DNA and the development of dysplasias (squamous intraepithelial lesions) or (for the quadrivalent vaccine) anogenital warts. These studies showed near-complete protection (>90% vaccine efficacy) that was type-restricted against vaccine-type HPV infection. In addition, there was 100% protection in preventing genital warts as well as low- and high-grade CIN, VaIN, and VIN that were associated with the vaccine HPV types (for at least 10 years)[5–7,88,89]. The quadrivalent vaccine was also found to be nearly 90% effective in preventing both genital warts caused by HPV types 6 and 11 in young men and AIN. While post-marketing evaluation of the duration of efficacy of the vaccines is ongoing, trial results have demonstrated stabilized antibody titers for at least 10 years after vaccination, suggesting induction of a strong B cell memory response. Also, in studies where girls and boys between the ages of 10 and 15 years were vaccinated, more than 99% have seroconverted, and they developed antibody titers that were even higher than those in women 16 to 23 years of age[90].

Because these first two commercial HPV vaccines contain HPV-16 and -18 VLPs, they induce protection against the two high-risk HPV types that together account for ~70% of cervical cancers and high-grade CIN. Of note, they may offer limited cross-protection against closely related HPV-31, -33, and -45. More recently, the 9-valent vaccine

Downloaded for Anonymous User (n/a) at Egyptian Knowledge Bank from ClinicalKey.com by Elsevier on March 10, 2024. For personal use only. No other uses without permission. Copyright ©2024. Elsevier Inc. All rights reserved.

(Gardasil®9) was licensed which contains VLPs for HPV-6 and -11 as well as high-risk HPV types 16, 18, 31, 33, 45, 52, and 58[91]. Together, these seven high-risk HPV types have been identified in ~90% of cervical cancers[9,21]. Because it is not 100%, vaccinated women should continue to have Pap smears performed.

The three HPV vaccines that have been introduced worldwide over the past fifteen years are aimed at achieving universal vaccination of children and adolescents, ideally at 11 or 12 years of age. This would be prior to the onset of sexual activity and when the strongest immune response is generated, with the CDC recommending "catch-up" shots for those ages 13–26 years. Four years after implementing a national quadrivalent HPV vaccine program in Australia that was aimed at girls and young women and resulted in 70% coverage, genital warts nearly disappeared in women and heterosexual men <21 years of age[21]. In addition, high-grade cervical lesions significantly declined[92], with both outcomes demonstrating vaccine effectiveness at the population level.

The 9-valent vaccine is FDA-approved for females and males ages 9 to 45 years to prevent anogenital warts as well as cervical, vulvar and vaginal cancers, anal cancer, and HPV-related head and neck cancers. Of note, both the bivalent and quadrivalent vaccines have been removed from the US market due to low demand, but are available in other countries. The CDC views vaccination of inadequately vaccinated adults 27 to 45 years of age as optional as a greater percentage of these individuals have already been exposed to HPV.

Because the HPV vaccines have no therapeutic efficacy against preexisting infection or disease, the benefit of vaccinating older patients is considerably smaller. To date, there are no randomized, placebo-controlled trials demonstrating therapeutic efficacy of licensed HPV vaccines in the treatment of genital, cutaneous, or laryngeal warts. Although vaccinating males (e.g. with Gardasil®) is less cost-efficient than vaccinating females, this intervention likely increases vaccine efficiency in the population as a whole due to herd immunity[4,86]. Vaccination is also expected to lead to a drastic reduction in anal dysplasia and cancer (particularly in MSM) as well as an estimated one-third reduction in the incidence of oropharyngeal cancer. In 2020, the WHO launched a 90-70-90 strategy for the global elimination of cervical cancer via the vaccination of 90% of girls by age 15 years, screening 70% of women by 35 years of age and again by 45 years of age, and treating 90% of women with cervical precancer or cancer.

Currently, HPV vaccines are approved for use as either two- or three-dose regimens according to age. However, questions remain regarding the duration of vaccine efficacy and cross-protection with two doses (or even one dose) as compared to three doses. To date, several hundred million doses of HPV vaccines have been administered with retention of a good safety profile. There is also no indication of replacement by non-vaccine-targeted HPV types. The information gained from ongoing studies will aid in answering additional questions, including: duration of protection (when to boost if at all); possible longer-term benefit of preventing re-infection; utility of (pseudovirion) surrogate assays for neutralizing antibodies; and correlates of protection.

As an alternative approach for generating broader-spectrum vaccines, genetic engineering has been employed to develop L1 VLPs that also express type-common epitopes of the minor capsid protein L2 (e.g. the highly conserved "RG1" peptide of HPV-16 L2 that contains a cross-neutralization epitope), which can induce cross-protective immunity to a variety of mucosal and even cutaneous HPV types[93–95]. In a preclinical genital challenge animal model, vaccination with HPV16 RG1-VLP provided broad protection against virtually all high-risk mucosal HPVs, in addition to inducing cross-neutralization against low-risk mucosal types, common cutaneous types (HPV-2, -27, -57, -3), and oncogenic β types (HPV-5, -8)[96]. As part of the US National Cancer Institute PREVENT program, a phase I first-in-human trial of a RG1-VLP vaccine candidate is planned. Such monovalent VLP vaccines may become a cost-effective alternative strategy for implementing national HPV vaccination programs, especially in low-income countries that cannot afford multivalent HPV vaccines or cytology (Pap) screening, yet carry >80% of the worldwide burden of cervical cancer[97,98].

Successful experiments in animals have encouraged efforts to develop *therapeutic* vaccines against HPV infections. Most papillomavirus infections are self-limited, and it is generally agreed that a cellular immune response (albeit poorly understood) is required for clearance of infection. Cell-mediated immunity to L1 or L2 is unlikely to exhibit therapeutic efficacy, as capsid proteins are expressed neither in basal cells that harbor HPV DNA nor in progressed lesions that do not produce virions. Candidate rejection antigens are the E6 and E7 oncoproteins, which are selectively retained and expressed in cervical dysplasia and cancer, and E1 or E2 proteins, which are required to maintain the viral genome as an episome. Multiple strategies have been employed, including vaccinations with papillomavirus proteins fused to or combined with immunostimulants or dendritic cells in addition to attenuated viral or DNA expression vectors[99].

Chimeric VLPs have been engineered to incorporate an early protein such as E7 into an L1 or L1/L2 capsid. The induction of cytotoxic T-lymphocyte responses to the E7 oncoprotein, in addition to antibodies directed against the L1 capsid protein, provides both therapeutic and prophylactic benefit in mouse tumor models[100]. These strategies may prove effective in low-grade dysplasia or condylomata that have a high likelihood of spontaneous regression. However, mechanisms of immune evasion such as down-regulation of MHC type I expression may diminish the success of therapeutic vaccines and, thus, favor their application as an adjunct to established ablative therapies. Also, safety issues associated with live attenuated or DNA vectors and with vaccines containing E6 or E7 oncoproteins are complex[86,101].

Additional figures available in our eBook (see inside front cover for access code).

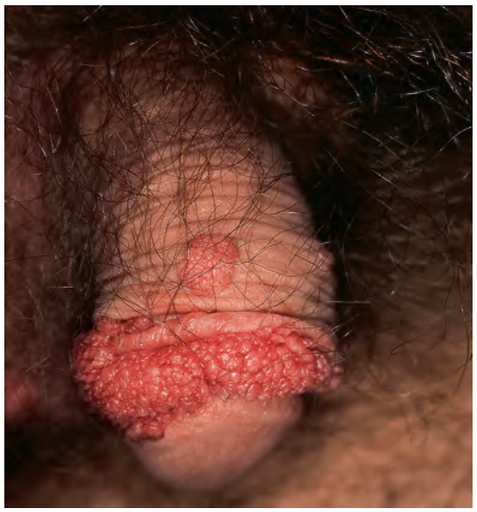

eFig. 79.7 Extensive and treatment-resistant condylomata acuminata of the penis in a renal transplant recipient.

eFig. 79.8 Condylomata acuminata. Perianal papillomas that are macerated due to moisture from occlusion.

eFig. 79.9 Perianal condylomata acuminata. *Courtesy Kalman Watsky, MD.*

eFig. 79.10 Verrucous carcinoma (papillomatosis cutis carcinoides of Gottron). Large well-demarcated tumor of the shin with histologic features of a highly differentiated squamous cell carcinoma.

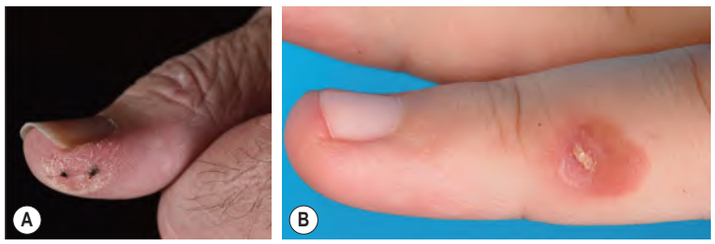

eFig. 79.11 Squamous cell carcinoma in situ (Bowen disease) of the finger. Periungual verrucous plaque (**A**) and well-demarcated, erythematous plaque with scale (**B**). Both harbored high-risk HPV DNA.

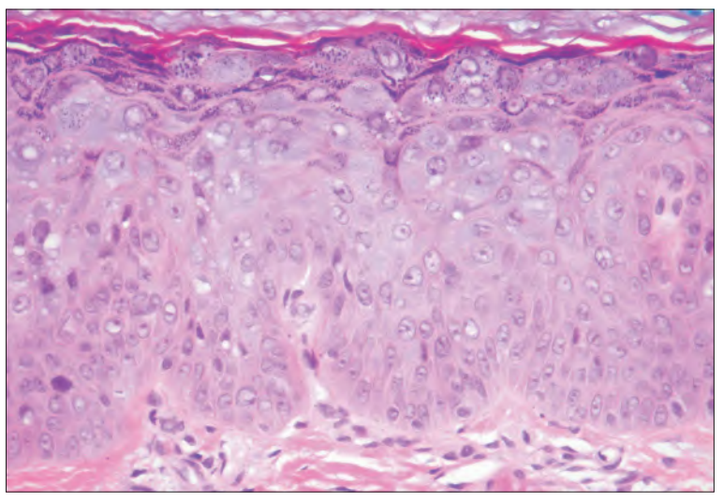

eFig. 79.12 Histology of epidermodysplasia verruciformis. Note the cells with blue–gray cytoplasm in the mid to upper epidermis. *Courtesy Mary S. Stone, MD.*

Downloaded for Anonymous User (n/a) at Egyptian Knowledge Bank from ClinicalKey.com by Elsevier on March 10, 2024. For personal use only. No other uses without permission. Copyright ©2024. Elsevier Inc. All rights reserved.

eFig. 79.13 Epidermal nevi that were misdiagnosed as condylomata acuminata. *Courtesy Kalman Watsky, MD.*

Downloaded for Anonymous User (n/a) at Egyptian Knowledge Bank from ClinicalKey.com by Elsevier on March 10, 2024. For personal use only. No other uses without permission. Copyright ©2024. Elsevier Inc. All rights reserved.